

Percutaneous fixation of acetabular fractures: Computer assisted determination of safe zones, angles and lengths for screw insertion.

Wolfgang Pichler¹, Paul Puchwein¹, Hans Clement², Christoph Grechenig¹, Wolfgang Grechenig²

¹Medical University of Graz, Department of Traumatology, Austria.

²Unfallkrankenhaus Graz, Austria

Three dimensional reconstructions of 50 consecutive CT scans of polytrauma patients (35 males, 15 females) were used to introduce three virtual CAD bolts (representing screws) into the anterior column, posterior column and the supraacetabular region, as performed during percutaneous screw fixation. The three dimensional (3D) position of these screws was evaluated with computer software after virtual optimal insertion.

The mean maximal screw length for the three virtual screws measured between 107.42 and 148±18.69mm. The narrowest zone of the pelvic bone (superior pubic ramus) had a width of 9.2±2.42 mm. The closest distance between the bolts and the hip joint was 1.18mm (pubic screw). For the anterior column (superior pubic ramus) screw the mean lateral angle to the sagittal midline plane was 39.02±3.17° and the mean posterior angle to the transversal midline plane 15.05±4.01°. The mean supraacetabular screw angles measured 22.39±3.4°(medial), 35.34±4.55° (cranial) and the mean angles for the ischial screw were 12.03±5.38° (posterior) and 18.38±4.02° (lateral).

The zones for safe screw positioning are very narrow, making percutaneous screw fixation of the acetabulum a challenging procedure. Results of this study may aid in preoperative planning, decrease operative and radiation times and help to increase safe insertion of screws.

The incidence of low-energy acetabular fractures is increasing among the elderly osteoporotic population (1–3). Controversy exists regarding the optimal treatment for these fractures in older and obese patients. Various treatment options have been described including nonoperative management, open reduction and internal fixations using plates and screws, minimally invasive stabilization and acute total hip arthroplasty (3–7). Early minimally invasive definitive stabilization of selected acetabular fractures is an attractive alternative to major open procedures, especially in the elderly patients who have multiple co-morbidities and a higher perioperative risk (4).

Percutaneous insertion of long screws into narrow safe zones (articular penetration, neurovascular

structures) around the acetabulum can be technically demanding due to the complex three-dimensional anatomy of the pelvis. There is limited data available regarding the optimal positioning of these screws during fixation of acetabular fractures (8–10).

The purpose of this study was to determine the optimal angles and maximum screw lengths with the help of a simulated fixation model on three dimensional 3D-CT reconstruction scans.

Material and methods

An analysis of 50 consecutive CT scans on polytrauma patients, who were admitted to a level I trauma centre over a 12-month period, was performed. Scans with

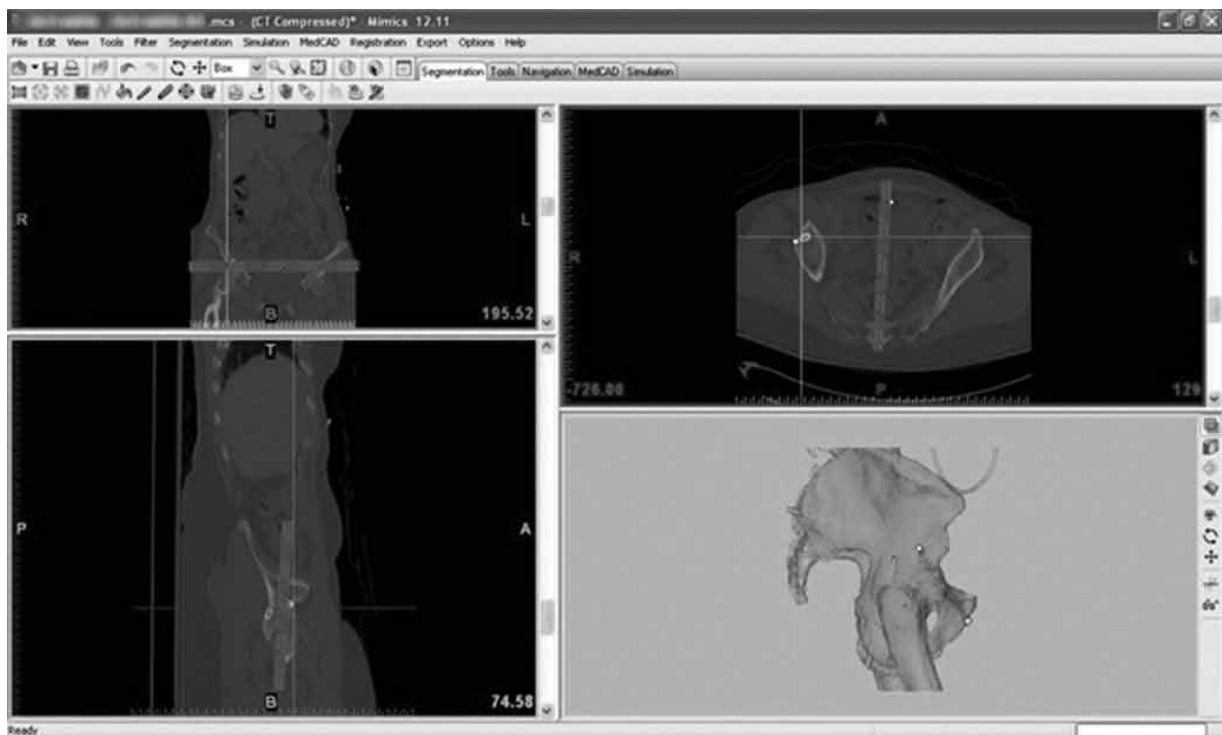


Figure 1: Overview of MIMICS Software. Three reference planes were used for the measurement of screw position angles (planes are marked using gray bars).

evidence of bony and/or ligamentous pelvic ring or acetabular injury or other pathology (primary or secondary malignancy, metabolic bone disease, severe degenerative changes, previous trauma) were excluded. All CT scans were performed using a 64-slice Siemens SOMATOM Sensation[®] CT system (Siemens Medical Solutions USA Inc., 51 Valley Stream Parkway, Malvern, PA 19355, United States). Patients were positioned supine and 0.6mm contiguous axial slices of the pelvis were used. CT scans were ordered based on clinical judgement and not for the purpose of this study. DICOM raw data sets were reconstructed using the 3D software MIMICS[®] (Materialise, Leuven, Belgium). All simulations and measurements were carried out using this particular software (11–13).

After obtaining 3D reconstructions of the original CT scans, the simulation of inserting virtual computer-aided design (CAD) bolts (diameter 7.3mm) was performed, positioning the three screws into the anterior column (superior pubic ramus), the posterior column (the ischium) and the supraacetabular region respectively. The exact position of each screw was based on the standard surgical technique previously described in the literature (5,7,10–16). The achieved position of each bolt was checked using the 3D re-

constructions and three different 2D images, taken in three different planes (axial, coronal and sagittal), thus enabling assessment of potential perforation into the pelvic ring or the hip joint.

The maximum screw length was measured between fixed points, using the entry point of each bolt and the exit point on the far cortex. The high risk zones with the smallest bolt-to-cortex distances were identified using three different 2D plane views. The overall diameter of the identified high risk zone and the distance from the entry point of the bolt were both measured with the help of further set points. The shortest distance between each bolt and the hip joint was separately evaluated.

Three reference planes were used for the measurement of screw position angles: sagittal (defined by the midline of symphysis and the midline of the sacrum), transverse (perpendicular to the sagittal plane) and coronal (perpendicular to the transverse plane) (Figure 1). The 3D MIMICS[®] software was used to measure the angles between the three CAD bolts and the respective reference planes.

All measurements were performed by two independent observers, both being trained and experienced users of the computer software used. To validate

the reproducibility and accuracy of the measurement protocol, each observer performed five sets of measurements on each specimen. The variation between measurements was $\pm 2.5\%$ for all the measured parameters. After establishing and verifying the measurement routine, further calculations of all angles and distances were performed by the MIMICS® software. The results were exported into Excel® file format. All statistical calculations were done using Microsoft Excel® 2003 (Microsoft Headquarters, Redmond, Washington, United States) Student t-test, testing for gender specific differences in measured parameters. A p-value of < 0.05 considered to be statistically significant. The study was approved by the Ethics Committee of the Medical University of Graz, Austria.

Results

Patient demographics showed 35 male and 15 female patients with a mean age of 41.3 ± 18.5 years (15-86 years) and 43.4 ± 21.9 years (17-87 years) respectively. The mean length of the anterior column (superior pubic ramus) screw was 127.2 ± 7.1 mm, with the mean distance from the entry point to the narrowest zone measuring 50.6 ± 6.3 mm. The narrowest point the superior pubic ramus measured 14.6 ± 2.4 mm, suggesting a small margin of error for a 7.3 mm screw. Figure 2 shows the close proximity of a well positioned pubic screw to the hip joint; the average distance between the bolt to and the hip joint was 3.9 ± 1.6 mm. The mean angle between the pubic ramus screw and the sagittal plane was $39.02 \pm 3.17^\circ$ (Figure 3), and the mean angle between the pubic ramus screw and the coronal plane was $15.05 \pm 4.01^\circ$ (Figure 4).

The mean screw length for the supraacetabular screw was 148 ± 9.4 mm, with a mean distance from the supraacetabular entry point to the narrowest zone measuring 17.5 ± 3.3 mm. The dimensions of the narrowest zone measured 16.0 ± 2.7 mm. The average distance between the bolt and the hip joint measured 19.4 ± 3.1 mm (Figure 5). The angle between the supraacetabular screw and the sagittal plane was $22.4 \pm 3.4^\circ$, whilst the mean angle between the screw and the transverse plane was $35.3 \pm 4.6^\circ$ (Figures 6,7).

The mean posterior column (ischium) screw length measured 107.4 ± 9.1 mm. The mean distance from the entry point to the narrowest zone measured 53.2 ± 6.8 mm. The narrowest zone of the ischial bone was 20.7 ± 2.7 mm. The average distance between the bolt and the hip joint was 5.2 ± 1.32 mm (Figure 8).




Figure 2: Distance between the pubic bolt and the hip joint.

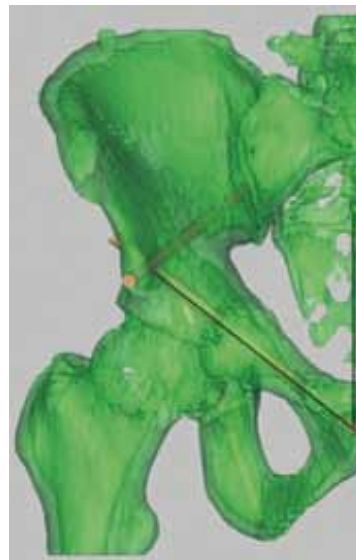


Figure 3: Pubic screw angle, lateral to the sagittal plane.

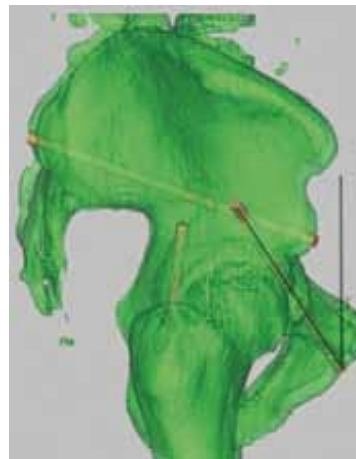


Figure 4: Pubic screw angle in the posterior projection to the coronal plane.



Figure 5: Distance measurement between the supraacetabular bolt and the hip joint.

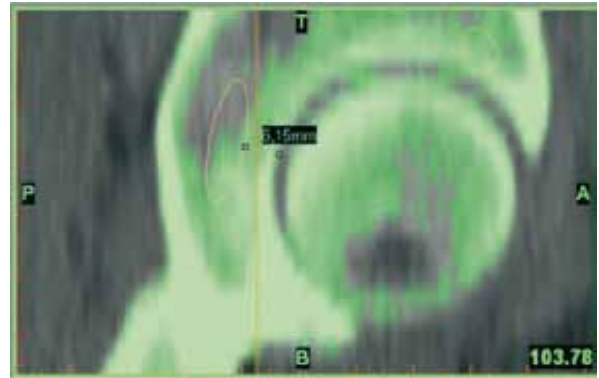


Figure 8: Distance measurement between the ischial bolt and the hip joint.

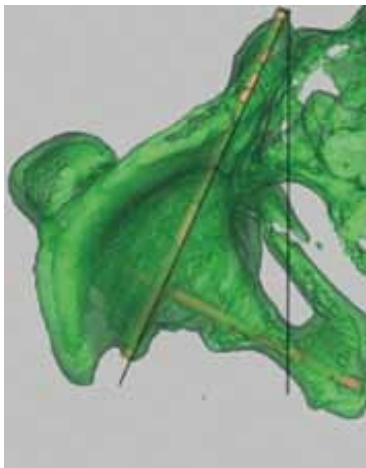


Figure 6: Supraacetabular screw angle medial direction to the sagittal plane.

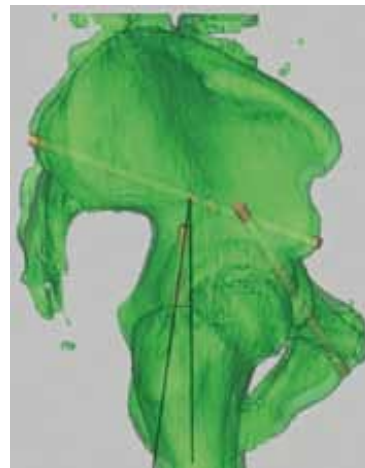


Figure 9: Ischial screw angle posterior direction to the coronal plane.

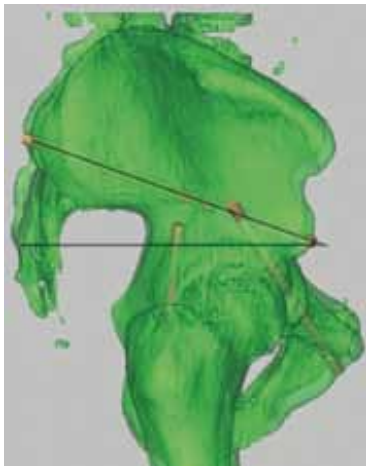


Figure 7: Supraacetabular screw angle cranial projection to the transversal plane.

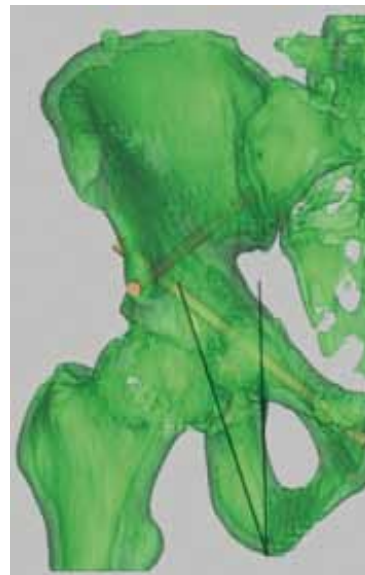


Figure 10: Ischial screw angle lateral projection to the sagittal plane.

Table 1: Summary of results and statistical correlations.

	mean	range	male	female	p-value (sex)
pubic screw					
maximal screw length (mm)	127.2 ±7.1	111.9 – 144.6	128.3 ±6.7	124.8 ±7.7	>0.05
distance entry point to the narrowest zone (mm)	50.6 ±6.3	33.2 – 62.0	49.9 ±6.4	52.1 ±5.8	>0.05
narrowest zone (mm)	14.6 ±2.4	9.2 – 20.2	15.0 ±2.0	13.4 ±2.9	0.03
distance to hip joint (mm)	3.9 ±1.6	1.2 - 5.8	2.9 ±1.6	5.0 ±0.6	0.02
angle lateral direction to the sagittal plane (degree)	39.0 ±3.2	32.3 – 45.2	39.2 ±3.3	38.7 ±3.1	>0.05
angle posterior projection to the coronal plane (degree)	15.1 ±4.0	5.4 – 23.1	15.4 ±3.8	14.2 ±4.5	>0.05
supraacetabular screw					
maximal screw length (mm)	148 ±9.4	127.2 – 163.9	150.9 ±8.2	141.1 ±8.4	<0.001
distance entry point to the narrowest zone (mm)	17.5 ±3.3	11.0 – 27.5	18.5 ±3.2	14.8 ±1.6	<0.001
narrowest zone (mm)	16.0 ±2.7	9.9 – 23.6	16.8 ±2.3	14.1 ±2.6	<0.001
distance to hip joint (mm)	19.4 ±3.1	14.8 – 25.1	21.0 ±3.2	17.7 ±2.3	>0.05
angle medial direction to the sagittal plane (degree)	22.4 ±3.4	14.4 – 31.2	23 ±3	20.9 ±3.9	<0.05
angle cranial projection to the transversal plane (degree)	35.3 ±4.6	24.8 – 46.9	35.1 ±3.9	35.9 ±5.9	>0.05
ischial screw					
maximal screw length (mm)	107.4 ±9.1	74.7 – 122.4	110.8 ±7.1	99.4 ±8.5	<0.001
distance entry point to the narrowest zone (mm)	53.2 ±6.8	17.9 – 65.9	54.8 ±6.3	49.4 ±6.5	<0.001
narrowest zone (mm)	20.7 ±2.7	13.4 – 26.9	21.6 ±2.1	18.7 ±2.8	<0.001
distance to hip joint (mm)	5.2 ±1.3	3.1 – 6.9	5.4 ±1.4	5.0 ±1.3	>0.05
angle posterior direction to the coronal plane (degree)	12.0 ±5.4	0.9 – 26.1	11.5 ±5.1	13.4 ±6.0	>0.05
angle lateral projection to the sagittal plane (degree)	18.4 ±4.0	7.9 – 27.9	19.6 ±3.1	15.5 ±4.7	<0.001

The mean deviation of the ischial screw from the sagittal plane was 12.0±5.4° and from the coronal plane was 18.38±4.02° (Figure 9,10).

There were multiple gender specific differences in the measured parameters which are summarized in table 1.

The safe zone for the anterior column screw (superior pubic ramus) was smaller in females (p =0.03) but the distance to the hip joint was bigger (p =0.02).

The supraacetabular screw was longer in males, with a longer distance from the supraacetabular entry point to the narrowest zone. However the narrowest

zone of the supraacetabular area was smaller in women. The posterior column screw (ischium) length was longer in men along with the distance from the ischial entry point to the narrowest zone. The narrowest zone of the ischial bone was smaller in females. The ischial screw angle in sagittal plane was higher in males. These gender specific measurements were all significant (p<0.001).

Discussion

There is currently little information about anatomical dimensions of the columns of the acetabulum and potential anatomical variations. The precise location and dimensions of hazardous zones, where a breach of the cortex and/or perforation of the hip joint is a common danger, is also poorly understood. None of the available literature describes precisely the exact three-dimensional position of the screw placement in regards to safe screw angles and lengths.

The orthopaedic literature contains few reports on minimally invasive fixation of acetabular fractures using percutaneous screws. Most reports focus on the surgical technique (5–7,14–18). In 1992 Gay et al. were the first to describe the percutaneous screw fixation technique for acetabular fractures. Their technique involved placing 2 cannulated screws above the acetabular roof (15). Starr et al. modified the technique by using 3 screws (7). This particular technique was used in our simulated procedure.

A case series of the same technique was described in Bates's study. He operated on seven obese patients with a low complication rate and overall satisfying clinical results. The author did not mention any measurements (5). A review of 21 consecutive geriatric patients with percutaneous screw fixation of acetabular fractures was done by Mouhsine and his colleagues. This series showed no intraoperative or postoperative complications and no radiographical evidence of secondary fragment displacement or implant failure (14). Although radiological follow up was performed, the author did not comment on the accuracy of screw placements.

Shahulhameed was the first to measure the bony thickness of the acetabular columns on cadavers. He collected data on 6 male and 5 female specimens where 1cm slices of the anterior and posterior columns were prepared. The measurements from the anterior column varied from 12.1 – 18.2mm and from the posterior column from 16.5 – 30.3. In comparison to our study, he used calipers and AO small-fragment depth gauges for his assessment (9).

In our study the described measurements of the narrowest zones and the distances from screw entry points to these zones were not done by simply measuring the cross-sectional diameters of the bone. We evaluated these zones along the three virtual CAD screws, hence these measurements objectively show the anatomical bottlenecks which are found during surgery.

Knowing the exact location and diameter of these areas might reduce the risk of bony and hip joint penetrations.

The potentially available intracortical space for each of the three screws was investigated by Attias's group in 2005. They used a virtual three-dimensional model. The authors measured the diameter of the available intraosseous space for the supraacetabular (10.5 – 13.3mm), the ischial (9.4 – 13.3mm) and the pubic screw (5 – 7.3mm). Virtual lengths were also measured. They used few specimens (13 in total) with no information about the gender distribution (10).

We have been unable to find any studies where the distances between the screws and the hip joint are measured. Perforation of the hip joint can be a potentially disastrous complication of this percutaneous procedure. In this study the virtual screws were often extremely close to the hip joint (as close as 1.18mm for the pubic screw). We positioned the virtual bolts with the help of three different 2D CT scan planes and the 3D reconstruction to find the optimal placement. In the majority of the clinical scenarios the percutaneous screws are inserted by using a 2D fluoroscope, thus achieving the same precision might not be possible. The more widespread use of 3D fluoroscope and computer navigated surgery might change this and give the surgeon an advantage with preoperative planning and during the procedure.

This has been shown by Ochs et al. who compared two different fluoroscopy based navigation techniques during percutaneous acetabular fixation. Three-dimensional-fluoroscopy based navigation showed a significantly lower screw perforation rate and screw malposition than 2D-fluoroscopy based navigation (8).

The ideal angles for achieving optimal screw positions are not known. We measured the angles of all three screws relating to the three planes of the body. Knowing these angles could be useful during the procedure, especially if no navigation system is available.

Conclusion

Minimal invasive screw fixation of acetabular fractures is a feasible option, and has several advantages especially in the obese and elderly patient. Knowing the precise location of the safe zones and the relevant distances to the hip joint could help reduce perforations into the hip joint, thus preventing complications and improving outcome.

References

1. Carroll EA, Huber FG, Goldman AT, Virkus WW, Pagenkopf E, Lorch DG, et al. Treatment of acetabular fractures in an older population. *J Orthop Trauma*. 2010 Oct;24(10):637-644.
2. Ferguson TA, Patel R, Bhandari M, Matta JM. Fractures of the acetabulum in patients aged 60 years and older: an epidemiological and radiological study. *J Bone Joint Surg Br*. 2010;92-B(2):250-257.
3. Mears DC. Surgical treatment of acetabular fractures in elderly patients with osteoporotic bone. *J Am Acad Orthop Surg*. 1999;7(2):128-141. Review.
4. Vallier HA, Cureton BA, Ekstein C, Oldenburg FP, Wilber JH. Early definitive stabilization of unstable pelvis and acetabulum fractures reduces morbidity. *JTrauma*. 2010;69(3):677-684.
5. Bates P, Gary J, Singh G, Reinert C, Starr A. Percutaneous treatment of pelvic and acetabular fractures in obese patients. *Orthop Clin North Am*. 2011;42(1):55-67.
6. Starr AJ, Jones AL, Reinert CM, Borer DS. Preliminary results and complications following limited open reduction and percutaneous screw fixation of displaced fractures of the acetabulum. *Injury*. 2001;32 Suppl 1:SA45-50.
7. Starr AJ, Reinert CM, Jones AL. Percutaneous fixation of the columns of the acetabulum: a new technique. *J Orthop Trauma*. 1998;12(1):51-58.
8. Kaempffe FA, Bone LB, Border JR. Open reduction and internal fixation of acetabular fractures: heterotopic ossification and other complications of treatment. *J Orthop Trauma*. 1991;5(4):439-445.
9. Shahulhameed A, Roberts CS, Pomeroy CL, Acland RD, Giannoudis PV. Mapping the columns of the acetabulum—implications for percutaneous fixation. *Injury*. 2010;41(4):339-342.
10. Attias N, Lindsey RW, Starr AJ, Borer D, Bridges K, Hipp JA. The use of a virtual three-dimensional model to evaluate the intraosseous space available for percutaneous screw fixation of acetabular fractures. *J Bone Joint Surg Br*. 2005;87-B(11):1520-1523.
11. Zhang YZ, Lu S, Chen B, Zhao JM, Liu R, Pei GX. Application of computer-aided design osteotomy template for treatment of cubitus varus deformity in teenagers: a pilot study. *J Shoulder Elbow Surg*. 2011;20(1):51-56.
12. Pichler W, Windisch G, Schaffler G, Heidari N, Dorr K, Grechenig W. Computer-assisted 3-dimensional anthropometry of the scaphoid. *Orthopedics*. 2010;33(2):85-88.
13. Pichler W, Windisch G, Schaffler G, Rienmüller R, Grechenig W. Computer tomography aided 3D analysis of the distal dorsal radius surface and the effects on volar plate osteosynthesis. *J Hand Surg Eur*. 2009;34(5):598-602.
14. Mouhsine E, Garofalo R, Borens O, Wettstein M, Blanc CH, Fischer JF, et al. Percutaneous retrograde screwing for stabilisation of acetabular fractures. *Injury*. 2005;36(11):1330-1336.
15. Gay SB, Siström C, Wang GJ, Kahler DA, Boman T, McHugh N, et al. Percutaneous screw fixation of acetabular fractures with CT guidance: preliminary results of a new technique. *Am J Roentgenol*. 1992;158(4):819-822.
16. Routt ML Jr, Simonian PT, Grujic L. The retrograde medullary superior pubic ramus screw for the treatment of anterior pelvic ring disruptions: a new technique. *J Orthop Trauma*. 1995;9(1):35-44.
17. Routt ML Jr, Nork SE, Mills WJ. Percutaneous fixation of pelvic ring disruptions. *Clin Orthop Relat Res*. 2000;375:15-29. Review.
18. Parker PJ, Copeland C. Percutaneous fluoroscopic screw fixation of acetabular fractures. *Injury*. 1997;28(9-10):597-600.